

Cricoid pressure in combination with the BURP maneuver versus cricoid pressure alone to improve the glottis view in pediatric patients; an interventional study

A.E. SOLTANI (*), F. REZAEI (*), M. GOUDARZI (*), A. BARATLOO (**), Z. H. KHAN (***), M. R. KHAJAVI (****)

Abstract : *Background :* Glottis view is the main determinant of successful tracheal intubation during direct laryngoscopy. When difficulties arise, external laryngeal manipulation is usually the first and simplest technique to facilitate glottis view at first intubation attempt.

Aim : This study was designed to evidence the efficacy of cricoid pressure in combination with the BURP maneuver as compared to cricoid pressure alone to improve glottis view during laryngoscopy for tracheal intubation in pediatric patients.

Methods : This trial was conducted on pediatric patients, candidate for elective surgery under general anesthesia. After induction, direct laryngoscopy was performed with a Macintosh blade by an experienced anesthesiologist, and assigned a score based on a Modified Cormack-Lehane classification (control view). Thereafter, on the same patients, cricoid pressure was applied by an assistant and glottis view was again scored. Finally, the BURP maneuver in combination with cricoid pressure was performed, and a score of glottis view was again obtained. Data were then compared within group, between the different types of manoeuvres (none, cricoid pressure alone, and BURP with cricoid pressure).

Results : In total, 150 cases with a mean age of 4.4 ± 1.6 years were enrolled, of whom 103 cases (68.7%) were males. Cricoid pressure + BURP maneuver during laryngoscopy improved the glottis view in 32% of patients as compared with the control view ($P=0.001$). Cricoid pressure alone worsened the view in 60% of patients as compared to the control view ($P=0.001$).

Conclusion : Cricoid pressure in combination with the BURP maneuver improves glottis view, while cricoid pressure alone worsens it in pediatric patients under general anesthesia.

Keywords : Laryngoscopy, Cricoid pressure, Sellick's maneuver, BURP maneuver, Pediatric, Glottis view.

Introduction

Glottis view is the main determinant of successive tracheal intubation during direct

laryngoscopy. In case of difficulties, external laryngeal manipulations are usually the first and simplest techniques to facilitate the view at first intubation attempt (1, 2). Bimanual laryngoscopy, BURP maneuver (backward, upward, and rightward pressure on the larynx) and cricoid pressure (or Sellick's maneuver) are among the known external laryngeal manipulation that are frequently used for improving glottis view and ease of tracheal intubation (3, 4).

The BURP maneuver was introduced by Knill in 1993, to improve the glottis view during tracheal intubation (5). The efficacy of this maneuver was validated by some authors in adult patients. In that population, they demonstrated significant improvement of the glottis view during attempts at endotracheal intubation (6). The cricoid pressure maneuver was described by Sellick in 1961, primarily to control for possible regurgitation. It was further used for better glottis visualization (7). Its efficacy at ameliorating laryngoscopic view is a matter of debate, because it was reported by some authors a worsening of the view after this manoeuver (8, 9). In the meantime, Snider et al. tried to assess

Alireza Ebrahim SOLTANI, M.D., Farhad REZAEI, M.D., Mehrdad GOUDARZI, M.D., Alireza BARATLOO, M.D., Zahid Hussain KHAN, M.D., Mohammad Reza KHAJAVI

(*) Department of Anesthesiology, Children's Medical Center, Tehran University of Medical Sciences, Tehran, Iran.

(**) Department of Emergency Medicine, Sina Hospital, Tehran University of Medical Sciences, Tehran, Iran.

(***) Department of Anesthesiology, Imam Khomeini Hospital Complex, Tehran University of Medical Sciences, Tehran, Iran.

(****) Department of Anesthesiology, Sina Hospital, Tehran University of Medical Sciences, Tehran, Iran.

Corresponding author : Dr. Mohammad Reza Khajavi, Department of Anesthesiology, Sina Hospital, Hasanabad Square, Tehran, Iran. Tel : +989123837096.
Email : khajavim@tums.ac.ir

Paper submitted on Feb 28, 2018 and accepted on Apr 28, 2019.

Conflict of interest: None

the impact of the combination of BURP maneuver with cricoid pressure in this regard, and found that this combination worsened the view in a significant number of cases (10).

Pediatric patients display anatomical differences as compared with adults. This has an impact on the techniques that the anesthesiologist might choose to provide safe and effective control of the airway (11). In addition, the efficacy of the BURP and Sellick maneuvers has not been well studied in this population. The available data on this topic are still scarce. This observational trial was designed to compare the efficacy of applying a combination of BURP maneuver and cricoid pressure, and cricoid pressure alone to improve glottis view during tracheal intubation in pediatric patients.

METHODS

Study design

This interventional study was conducted from February 2012 to January 2013 in the Children's Medical Center, Tehran, Iran. The study protocol had been approved by the Ethics Committee of the Tehran University of Medical Sciences. Informed consent was received from the parents. The investigators adhered to declaration of Helsinki - ethical principles for medical research involving human subjects - throughout the study.

Study population

This trial was conducted on 150 elective patients, ASA I-II (2-8 years old) candidates for general anesthesia and oro-tracheal intubation. Surgical procedures included urological procedures, inguinal hernia repairs, and orthopedic procedures, for which the children required general anesthesia.

We excluded patients with limited neck extension, full stomach, history of tracheal or laryngeal injury, difficult intubation (11, 12), body mass index (BMI) greater than 35 Kg/m², any anatomical anomaly in head, neck, and oropharynx, and those with history of gastro-esophageal reflux. Based on the data of the Snider paper, a power analysis was performed to determine the number of patients needed for the study (10). Sampling was performed via convenience method.

Intervention

In the operating room and following the necessary assessment, an intravenous (IV) access

was established and the appropriate monitors attached. After pre-oxygenation, each patient was pre-medicated with 0.05-0.1 mg/kg of intravenous midazolam, and 1 µg/Kg of fentanyl immediately before the administration of the induction agent. Thereafter, inhalation anesthesia was used for induction, using sevoflurane at a 6-7% inspired concentration. Thirty second after induction, after having reached the desired depth of anesthesia (40 < bispectral index > 60), the patients were put on the sniff position. An experienced anesthesiologist performed all laryngoscopies, using a Macintosh blade (aged-adjusted size), and one trained assistant performed all airway maneuvers during the study. At first, the anesthesiologist viewed the glottis during laryngoscopy and assigned a score from 1, 2a, 2b, 3, or 4, based on a Modified Cormack-Lehane classification (13).

The cricoid cartilage was identified and verified both by the assistant and anesthesiologist, and cricoid pressure was performed by the assistant. Glottic view grade was again noted. Finally, the BURP maneuver in combination with a cricoid pressure was performed, and the score of glottic view was again acquired.

Statistical analysis

Statistical analysis was performed using SPSS version 14. Descriptive data were presented as mean ± standard deviation (SD), numbers, or percentages. Student's t-test and ANOVA was used to compare the mean of quantitative variables within and between the groups. Qualitative variables were analyzed using Chi-square and Wilcoxon tests. A P-value < 0.05 was considered statistically significant.

RESULTS

One hundred and fifty patients, with a mean age of 4.4 ± 1.6 years (range: 2-6 years old) were enrolled, of whom 103 cases (68.7%) were males. The mean weight of the patients was 15.7 ± 5.6 Kg (range : 9-34 Kg). Demographic data, with repartition as a function of glottis view are shown in Table 1.

There were no episodes of significant desaturation (the least oxygen saturation was 96%) or regurgitation during the laryngoscopies and manipulations. Intubation was successful in all cases regardless of the applied maneuver. Complete details on glottis view grading with each maneuver are listed in Table 2.

Table 1

Comparison of demographic variables as a function of glottis view for each study condition

Maneuver	Variables	Grade 1	Grade 2a	Grade 2b	Grade 3*	Grade 4*	P
Without maneuver (control cases)	Male [n(%)]	50 (48.5)	48 (46.6)	5 (4.8)	0 (0.0)	0 (0.0)	0.29
	Female [n(%)]	25 (53.3)	22(46.8)	0 (0.0)	0 (0.0)	0 (0.0)	
	Age (year)	4.5 ± 2.6	4.4 ± 2.6	3.0 ± 0.0	-	-	0.47
	Weight (kg)	15.7 ± 5.6	15.0 ± 5.9	16.0 ± 1.1	-	-	0.98
Cricoid pressure	Male [n(%)]	14 (13.6)	65 (63.1)	24 (23.3)	0 (0.0)	0 (0.0)	0.0001
	Female [n(%)]	21 (44.7)	17 (36.2)	9 (19.1)	0 (0.0)	0 (0.0)	
	Age (year)	4.5 ± 1.8	4.8 ± 2.9	3.5 ± 1.6	-	-	0.014
	Weight (kg)	15.5 ± 3.6	16.7 ± 5.8	13.7 ± 6.6	-	-	0.054
Cricoid pressure + BURP	Male [n(%)]	83 (80.6)	20 (19.4)	0 (0.0)	0 (0.0)	0 (0.0)	0.727
	Female [n(%)]	39 (82.9)	8 (17.1)	0 (0.0)	0 (0.0)	0 (0.0)	
	Age (year)	4.6 ± 2.8	3.5 ± 2.1	-	-	-	0.038
	Weight (kg)	15.8 ± 5.6	15.2 ± 5.6	-	-	-	0.5

*There were no patients with grade 3 or 4 Cormack-Lehane

Table 2

Comparison of glottis views grading with each maneuver

Maneuver	Grade 1	Grade 2a	Grade 2b	Grade 3*	Grade 4*
	Number (%)				
Without maneuver (Control)	75 (50.0)	70 (46.7)	5 (3.3)	0 (0.0)	0 (0.0)
Cricoid pressure	35 (23.3)	82 (54.7)	33 (22.0)	0 (0.0)	0 (0.0)
Cricoid pressure + BURP	122 (81.3)	28 (18.7)	0 (0.0)	0 (0.0)	0 (0.0)

*There were no patients with grade 3 or 4 Cormack-Lehane

Table 3

Comparison of glottis view changes with each maneuver

Comparison	Without change	Improve view	worse view	P
	Number (%)			
Cricoid pressure vs. control	38 (25.3)	22 (14.7)	90 (60.0)	0.001
Cricoid pressure + BURP vs. control	99 (66.0)	49 (32.7)	2 (1.3)	0.001
Cricoid pressure + BURP vs. cricoid pressure	33 (22.0)	113 (75.3)	4 (2.7)	0.001

Comparison of glottis view changes with each maneuver are reported in Table 3 and Figure 1. Cricoid pressure in combination with BURP maneuver during laryngoscopy improved the view in 32% of patients as compared with the control view ($P=0.001$). Cricoid pressure alone worsened the view as compared to the control one in 60% of patients ($P=0.001$).

Cricoid pressure increases the grading of glottis view more in male than in female patients. The younger (< 3 year old) and lower weight patients had worst view with cricoid pressure. Cricoid pressure with BURP maneuver improved the glottis view without any significant correlation with demographic variables.

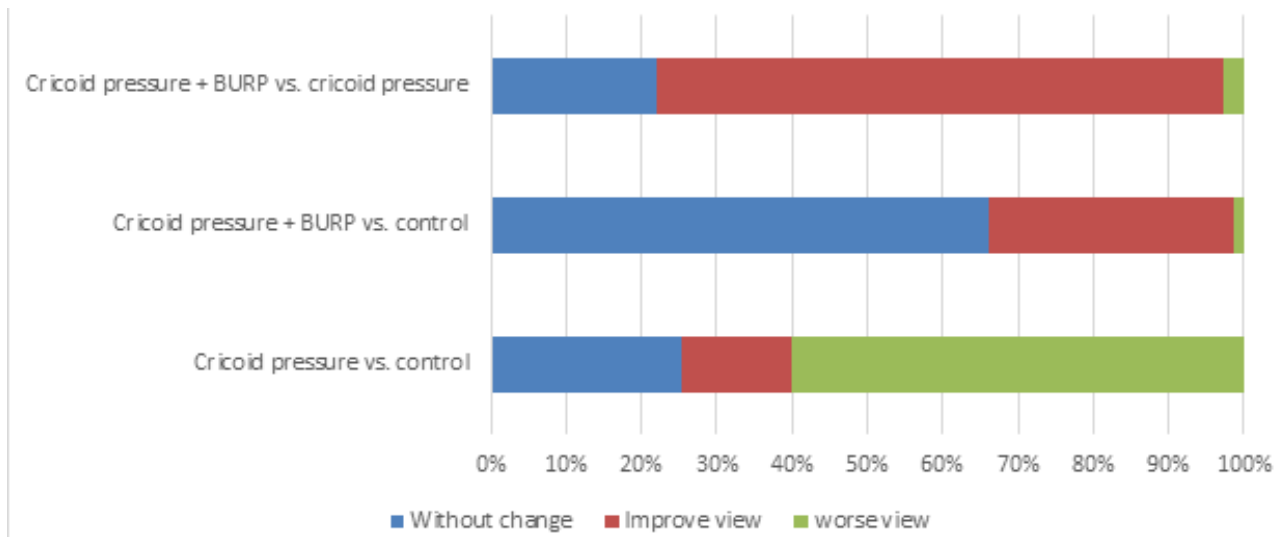


Fig. 1 — Comparison of glottis view changes with each maneuver.

DISCUSSION

Cricoid pressure associated with the BURP maneuver has a significant effect for better glottis view. It seems that cricoid pressure alone worsens the view, but this effects seems to depend on age, gender and weight. It worsens the view more in younger male patients with lower weight. In contrast, cricoid pressure associated with the BURP maneuver improves glottis view without any significant correlation with the demographic variables of the patients.

Reviewing current literature on pros and cons of external laryngeal manipulation shows considerable controversies. In a study conducted by Levitan *et al.* using a cadaver model, both cricoid pressure and BURP frequently worsen laryngoscopy (14). In a study by Haslam *et al.*, the effect of cricoid pressure on direct rigid laryngoscopy is individualized and the force on cricoid must be adjusted in each patient to provide the best view (15). In another study, Oh J *et al.* show that the application of cricoid pressure with increasing force results in a worse glottis view, as examined with the Pentax-AWS Video laryngoscope (16). Also in another study, the improved glottis view could be further enhanced by applying cricoid pressure with the BURP maneuver (17). In contrast, another study demonstrates that the combination of the BURP maneuver with cricoid pressure worsens the laryngoscopic view in 30% of cases, and suggests that there is no benefit in routinely adding the BURP maneuver when cricoid pressure is applied (10).

Usually, pediatric anesthesiologist, because of potential airway obstruction and the associated

technical problems, question the necessity and reliability of cricoid pressure (18, 19). To the best of our knowledge, there is not any study comparing these two external laryngeal manipulation in pediatric patients. All available studies have been conducted in adults with different anatomical airways as compared to children. In our study, grade 2b laryngoscopic view was reported in 33 (22%) of cases when cricoid pressure was applied, while grade 2b was not observed during cricoid pressure with BURP maneuver. It seems that pressure on the cricoid causes a cone-shaped base of the larynx with a posterior shift, and an anterior shift of the upper segment of the larynx, worsening the glottis opening. The BURP maneuver can modify this displacement, and improve glottis view when used in combination with cricoid pressure.

Limitations

This was a single-center observational trial that could not consider the possible role of race and anthropometric indexes. We also did not measure the pressure on the cricoid. There were no infants enrolled in the study; knowing that the glottis is antero-superiorly positioned in an infant as compared with an older child, not having data on infants (a pediatric patient group for whom many studies have shown worsened success rates and increased complication rates) constitutes a significant limitation to the generalizability of our findings. There were no patients with Cormack-Lehane Grade 3 or 4, which could limit the relevance of our results.

CONCLUSION

In conclusion, the combination of cricoid pressure and BURP maneuver improves glottis view during laryngoscopy under general anesthesia in pediatric patients. However, cricoid pressure alone, particularly in younger male pediatric patients, may worsen glottis view during laryngoscopy.

ETHICAL CONSIDERATION

The study protocol had been approved by the Ethical Board Committee of Anesthesiology, Department of Tehran University of Medical Sciences and Institutional Review Board approval has been assigned. It has been registered in the Iranian Registry of Clinical Trials and the code of IRCT201303098435N3 has been assigned to it. Written informed consent was obtained from all parents of patients and the investigators adhered to the Helsinki Principles throughout the study. The whole process was performed in less than 30 seconds and there was no concern regarding delay for intubation.

References

- Knopp R.K. 2002. External laryngeal manipulation: a simple intervention for difficult intubations. *Ann Emerg Med.* 40 : 38-40.
- Motamedi M., Soltani M., Amiri M., Memary E. and Baratloo A. 2017. Evaluating the Correlation between Intratracheal Intubation Difficulty Scoring Systems and Anthropometric Factors of Individuals' Body; an Epidemiologic Study. *Iran J Emerg Med.* 4 :68-73.
- Takahata O., Kubota M., Mamiya K., Akama Y., Nozaka T. and Matsumoto H. et al. 2017. The efficacy of the "BURP" maneuver during a difficult laryngoscopy. *Anesth Analg.* 84 : 419-421.
- Levitan R.M., Mickler T. and Hollander J.E. 2002. Bimanual laryngoscopy: a videographic study of external laryngeal manipulation by novice intubators. *Ann Emerg Med.* 40 : 30-37.
- Knill R.L. 1993. Difficult laryngoscopy made easy with a "BURP". *Can J Anaesth.* 40 : 279-282.
- Onda M., Inomata S., Satsumae T. and Tanaka M. 2012. The efficacy of the "BURP" maneuver during laryngoscopy and training period necessary for residents in anesthesiology. *Masui.* 61 : 444-7.
- Sellick B.A. 1961. Cricoid pressure to control regurgitation of stomach contents during induction of anaesthesia. *Lancet.* 2 : 404-6.
- Vanner R. 2009. Cricoid pressure. *Int J Obstet Anesth.* 18 : 103-105.
- Salem M.R., Khorasani A., Zeidan A. and Crystal GJ. 2017. Cricoid Pressure Controversies: Narrative Review. *Anesthesiology.* 126 : 738-752.
- Snider D.D., Clarke D. and Finucane B.T. 2005. The "BURP" maneuver worsens the glottic view when applied in combination with cricoid pressure. *Can J Anaesth.* 52 : 100-104.
- Mirghassemi A., Soltani A.E. and Abtahi M. 2011. Evaluation of laryngoscopic views and related influencing factors in a pediatric population. *Paediatr Anaesth.* 21 : 663-667.
- Gupta S., KR R.S. and Jain D. 2005. Airway assessment: Predictors of difficult airway. *Indian J Anaesth.* 49 : 257-262.
- Koh L.K., Kong C.E. and Ip-Yam P.C. 2002. The modified Cormack-Lehane score for the grading of direct laryngoscopy: evaluation in the Asian population. *Anaesth Intensive Care.* 30 : 48-51.
- Levitan R.M., Kinkle W.C., Levin W.J. and Everett W.W. 2006. Laryngeal view during laryngoscopy: a randomized trial comparing cricoid pressure, backward-upward-rightward pressure, and bimanual laryngoscopy. *Ann Emerg Med.* 47 : 548-555.
- Haslam N., Parker L. and Duggan J.E. 2005. Effect of cricoid pressure on the view at laryngoscopy. *Anaesthesia.* 60 : 41-47.
- Oh J., Lim T., Chee Y., Kang H., Cho Y. and Lee J. et al. 2013. Videographic analysis of glottic view with increasing cricoid pressure force. *Ann Emerg Med.* 61 : 407-413.
- Vanner R.G., Clarke P., Moore W.J. and Raftery S. 1997. The effect of cricoid pressure and neck support on the view at laryngoscopy. *Anaesthesia.* 52 : 896-900.
- Priebe H.J. 2010. Cricoid force in children. *Br J Anaesth.* 104 : 511.
- Weiss M. and Gerber A.C. 2008. Rapid sequence induction in children -- it's not a matter of time! *Paediatr Anaesth.* 18 : 97-99.